

Ossification of the midpalatal suture after surgically assisted rapid maxillary expansion

Júlio de Araújo Gurgel, Márcia Ferreira Vasconcelos Malmström and
Célia Regina Maio Pinzan-Vercelino

Department of Orthodontics, University Center of Maranhão, São Luis, Brazil

Correspondence to: Dr Júlio de Araújo Gurgel, Rua Coronel José Braz, 480 Centro, 17501-570 Marília, SP, Brazil.
E-mail: gurgelja@hotmail.com

SUMMARY The purpose of this study was to evaluate ossification of the midpalatal suture in adult patients immediately after surgically assisted rapid maxillary expansion (SARME) until 120 days post-surgery. The sample comprised 126 standardized occlusal radiographs of 21 adults (14 females and 7 males; mean age: 25.33 years) taken pre-expansion (T1), immediately after expansion (T2), and post-expansion (30, 60, 90, and 120 days of retention, respectively: T3, T4, T5, and T6) who had undergone SARME. The radiographs were digitized and the images were analysed and compared in relation to the morphology and radiopacity at the different treatment stages, especially concerning the characteristics of the midpalatal suture. Data were statistically analysed using analysis of variance and Tukey's test.

The results demonstrated that from T2 to T6, the mean optical density (OD) increased. However, these values were not similar to those observed at T1. A retention period of 120 days was not sufficient for the re-establishment of OD and complete ossification within the suture in the evaluated patients.

Introduction

Rapid maxillary expansion (RME) has been effectively used to correct transverse maxillary discrepancies in children and adolescents up to the pubertal stage (Bell, 1982; Pogrel *et al.*, 1992; Atac *et al.*, 2006; Babacan *et al.*, 2006). Separation of the maxillary bones in the midpalatal suture is achieved when the force applied to the dentoalveolar structures exceeds the limit required for orthodontic movement, priming the cell reaction in the periodontal ligament, and favouring the dissipation of forces to the maxillary sutures (Bell, 1982; Bishara and Staley, 1987). However, in adult patients, orthopaedic maxillary expansion is more difficult to achieve (Atac *et al.*, 2006; Babacan *et al.*, 2006) because of the increased rigidity of the craniofacial structures due to the presence of synostosis, bone bridges in the midpalatal suture, and greater resistance to distribution of expansion forces by the centre of resistance (Glassman *et al.*, 1984; Betts *et al.*, 1995; Proffit *et al.*, 1996; Northway and Meade, 1997; Berger *et al.*, 1998). Even though this increased rigidity is variable, it poses greater resistance to forces applied to the suture during maxillary expansion in patients after the pubertal growth spurt (Melsen, 1975; Bell, 1982).

Surgically assisted rapid maxillary expansion (SARME) is a therapy indicated for adults and young patients who have already reached skeletal maturity or for those in whom RME has been unsuccessful (Glassman *et al.*, 1984; Pogrel *et al.*, 1992; Betts *et al.*, 1995; Proffit *et al.*, 1996; Holberg *et al.*, 2007).

The period of post-expansion retention of the midpalatal suture plays a fundamental role in orthodontic treatment; during this period there is ossification of the suture, minimizing the possibility of relapse (Ekström *et al.*, 1977; Haas, 1980; Bell, 1982; Kahl-Nieke, 1996). The biological behaviour of the midpalatal suture in adults who have undergone SARME has not been fully clarified, especially in relation to the correct retention period to allow complete remodelling of the area, with a view to improving treatment stability (Anttila *et al.*, 2004; Byloff and Mossaz, 2004; Suri and Taneja, 2008).

As increasing numbers of adults are presenting for orthodontic treatment and in many cases correction of skeletal transverse discrepancy is required, the purpose of this study was to evaluate ossification of the midpalatal suture in adults undergoing SARME, up to and including a 120 day retention period.

Subjects and methods

The subjects received oral and written information of the aim and design of the investigation and all subjects gave their informed consent. The study was approved by the local ethics committee of Bauru Dental School, University of São Paulo.

After clinical evaluation and analysis of the orthodontic records of patients who initially had a maxillary transverse discrepancy, 21 adults (14 females and 7 males, with an initial mean age of 25.33 years and range 18.33–41.66

years) were prospectively selected. The criteria for sample selection included: transverse maxillary skeletal deficiency of more than 5 mm; presence of the maxillary first premolars and maxillary first or second molars on both sides, with good structural and periodontal conditions to allow cementation and activation of the fixed expansion appliance; and no pre-existing medical contraindication towards surgery.

One hundred and twenty-six standardized occlusal radiographs of the 21 adult patients who underwent SARME, taken pre-expansion (T1), immediately after expansion (T2), and post-expansion at 30 (T3), 60 (T4), 90 (T5), and 120 (T6) days of retention were assessed.

SARME was performed according to the technique described by Bell (1992). Hyrax expander appliances were used with a range of expansion from 7 to 9 mm, incorporating bands on the first permanent molars and premolars. The initial 2 mm activation of the expander was applied soon after suture opening. At 48 hours post-surgery, activation was continued with a 0.5 mm turn in the morning and at night, until achievement of the desired amount of expansion. The appliance was kept in place throughout the study period.

The maxillary occlusal radiographic technique was used in order to obtain radiographs with occlusal radiographic film (Kodak Insight, Rochester, New York, USA). The dental X-ray machine (General Electric, Waukesha, Wisconsin, USA) was set at 10 mA and 70 kV. All radiographs were taken by a single operator (MFVM).

The radiographs were digitized on a ScanMaker 9800XL (Microtek International Inc., Cerritos, California, USA), with a maximum optical resolution of $\times 1600$ 3200 dpi, a charge-coupled device sensor, 48-bit A/D converter, transparency adapter (Microtek International Inc.), and the respective software for image capture, ScanWizard (Microtek International Inc.). The optical density (OD) of the images was analysed using Adobe Photoshop CS3 Extended software (Adobe Systems Inc., San Jose, California, USA) on a standard IBM personal computer.

The radiographs were digitized at 600 dpi, 8 bits, greyscale, and stored in TIFF format without image compacting. After digitization, the images were cropped on the right and left sides, from the centre to the lateral margins of the expansion screw; superiorly on the margin of the radiographic image; and inferiorly at a tangent to the incisal aspects of the maxillary incisors, resulting in smaller files with an approximate size of 820 KB, which exhibited the entire extent of the midpalatal suture centralized on the image, thus enhancing the storage of the images for reading.

Three areas were determined with a fixed size of 24×24 pixels, corresponding to a surface of 1 mm^2 , in the midpalatal suture. One area was delineated in the anterior region and two in the posterior region: the first, 'A', was located on the alveolar crest between the maxillary incisors, the second, 'B', in the most posterior suture region at a tangent to the lower margin of the screw, and the third, 'C', was positioned

in the most posterior suture region opposite to area B but at the same level of the lower margin of the screw (Figure 1). On post-expansion radiographs, area A was determined as half the distance between the alveolar crests, which were then separated, as well as the maxillary incisors.

After delineation of the areas, the software provided a histogram demonstrating the mean pixel values. The values are the numerical representation of pixels in a greyscale ranging from 0, representing black, to 255, representing white. Data provided on the histogram were recorded on a specially designed form.

Evaluation of the digital and conventional occlusal radiographs was undertaken by a single radiologist (MFVM). The analysis addressed the initial characteristics of the suture, confirmation of suture opening, and presence of ossification of the midpalatal suture. The images were observed and compared with regard to the morphology and radiopacity at the different treatment stages and in particular the digital characteristics of the midpalatal suture on the final radiograph compared with the initial radiograph.

Statistical analysis

Statistical analysis was performed with analysis of variance, at a significance of 0.05. When the results showed a statistically significant difference, Tukey's test was applied to compare the groups individually.

Randomly selected radiographs of five patients were re-digitized and remeasured by the same examiner after a period of 4 weeks, a total of 30 radiographs. The random error was calculated according to the formula of Dahlberg (1940) and the systematic error with a dependent *t*-test (Houston, 1983), for $P < 0.05$.

Results

No statistically significant systematic intra-examiner errors were detected (A: $P = 0.142$, B: $P = 0.178$, and C: $P = 0.288$) and the random errors were within acceptable levels, with all variables below 1 pixel.

Comparison of pixel values of the areas evaluated at the different treatment stages revealed that no patient reached the values observed on the T1 images throughout the 120 day study period. This difference in OD values was significant for all areas ($P < 0.05$; Table 1).

Visual analysis of conventional occlusal radiographs

The characteristics of ossification observed during visual analysis of the radiographs are shown in Figures 1A–1F.

Discussion

Utilization of digitized imaging allows quantitative analysis of radiographs since it converts analogue to numeric data, which may be objectively analysed and compared. It aims

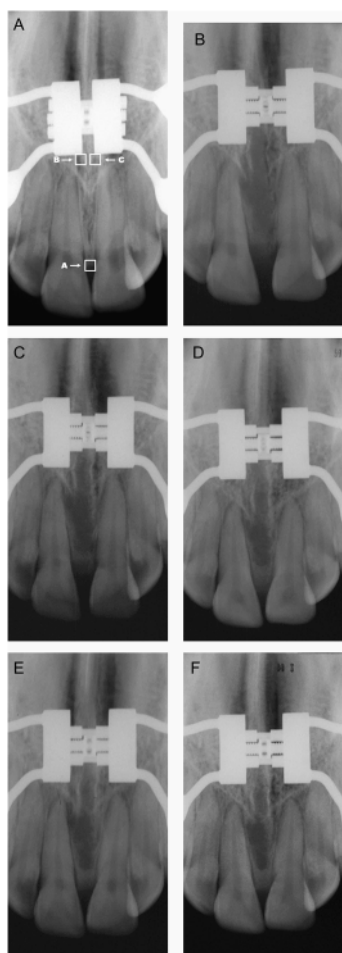


Figure 1 Occlusal radiographs of a 20.75-year-old patient. (A) Pre-expansion characteristics of sutures: showing variations on observation of the radiolucent space among bone margins, with definitions between straight, sinuous, interdigitated, and little visible sutures. (B) Immediately post-expansion visualization of suture opening: opening was observed as a triangular-shaped radiolucent area, with the base in the region between the central incisors and the vertex in the posterior region; some sutures exhibited a more parallel opening pattern. Bone margins: some were well defined, while others presented with radiopaque fragments attached or close to the bone margins or within the expanded area. (C) 30 days retention. Increased radiolucent area compared with T2, both in the width and in the length. Some sutures presented more parallel opening. A slight increase in radiopacity was observed in a diffuse manner throughout the extent of the suture. Bone margins: lower definition of margins and radiopaque fragments. (D) 60 days retention. Bone margins were less defined. Only one patient presented maintenance of the old cortical plates, radiographically observed as more radiopaque lines along the area of suture opening bilaterally. Ossification: on some radiographs, it was possible to observe areas with increased radiopacity, especially in the posterior region and close to the bone margins. Diffuse radiopacity similar to T3 throughout the expanded area. (E) 90 days retention. Ossification: mineralization of the bone margins was more evident, with a diffuse appearance in a transverse direction, perpendicular to the old bone margins of the suture. Increased radiopacity in the posterior region and lateral margins. A slight increase in radiopacity at the alveolar crest between the maxillary incisors. (F) 120 days retention. Ossification: gradual increase of radiopacity in the posterior region towards the medium region of the suture, from the bone margins towards the centre and onset of remodelling of the alveolar crest close to the roots of the maxillary incisors. The central area of the suture presented small radiopacity compared with the T1 radiograph. Bone margins: diffuse aspect, without definition of margins. Reduction of the diastema was observed

to increase the accuracy of image interpretation since radiographic diagnosis is subjective and depends on the experience and knowledge of the professional, image quality, and conditions for visualization, which may impair the visualization of details, interpretation of images, and diagnostic decisions (Attaelmanan *et al.*, 2000; Van Der Stelt, 2000).

OD analysis with digitized occlusal radiographs has been used as an advantageous and highly accurate method to determine bone formation and mineralization of the midpalatal suture after SARME (Cobo *et al.*, 1992; Sannomiya *et al.*, 2007).

The opening of the midpalatal suture has its base in the lower anterior region and fulcrum in the upper posterior region, towards the nasal cavity. The image observed on the occlusal radiograph reveals a V-shaped radiolucent region, with the base in the anterior region between the central incisors, usually separated by a diastema indicating greater space created anteriorly, and the vertex in the posterior region (Brosh *et al.*, 1998). Selection of the three reading areas was based on the characteristics of opening and remodelling of the midpalatal suture.

The results of the present study confirm some findings in the published literature relating to the type of opening of the midpalatal suture subjected to expansion forces, greater in the anterior region when compared with the posterior region (Sannomiya *et al.*, 2007; Garrett *et al.*, 2008; Lione *et al.*, 2008). Radiographically, a wide radiolucent area was observed between the bone margins of the palatal processes of the maxilla, with in some cases, a well-defined triangular shape and parallel bone margins in others, not allowing visualization of the vertex in the radiograph and hence indicating that opening also occurred towards the palatal bones.

The anterior region is reported in the literature as the last region to complete remodelling, being the area of the palate with the widest opening. Ossification occurs from the bone margins to the midline and is initiated in the posterior region of the suture (Brin *et al.*, 1981; Kanekawa and Shimizu, 1998; Arat *et al.*, 2003). The anterior area, A, had comparatively lower pixel values compared with the other two posterior areas evaluated at all treatment stages, corroborating the observations of a previous study (Sannomiya *et al.*, 2007), since these values indicated a lower radiopacity of this region.

Evaluation of the means revealed the pattern of variation of OD, with a significant decrease in density after activation, corresponding to opening of the midpalatal suture, and a gradual increase in radiopacity at T3. There was an increase in values from T5 to T6; however, pixel densities at T6 did not reach the values observed at T1. The T6 pixel values were 20.1 per cent lower than the initial values for area A and 23.7 and 19.34 per cent lower for areas B and C, respectively.

Individual variations were observed during visual analysis of the radiographs, which showed differences in

Table 1 Mean values and standard deviations (SD) of areas A, B, and C at pre-expansion (T1), post-expansion (T2), 30 (T3), 60 (T4), 90 (T5), and 120 day (T6) retention periods. Analysis of variance and Tukey's test.

Stage areas	T1, mean (SD)	T2, mean (SD)	T3, mean (SD)	T4, mean (SD)	T5, mean (SD)	T6, mean (SD)
A (area on the alveolar crest between the maxillary incisors)	85.6 ^A (16.9)	60.9 ^B (17.1)	67.6 ^B (18.5)	64.2 ^B (17.8)	62.2 ^B (15.9)	68.4 ^B (20.3)
B (area in the most posterior suture region at a tangent to the lower margin of the screw)	116 ^C (20.4)	80.7 ^D (24.4)	86.5 ^D (24.7)	87 ^D (25.2)	82.7 ^D (23.7)	88.5 ^D (22.2)
C (area in the most posterior suture region opposite to area B, at the same level of the lower margin of the screw)	109.1 ^E (21.8)	79 ^F (21.2)	84.9 ^F (22.3)	84.1 ^F (25.7)	82.5 ^F (24.1)	88 ^F (21.9)

Different letters represent statistically significant differences ($P < 0.05$) between the stages evaluated. The same letters in the different stages indicate that optical density was similar.

the amount and shape of the opening of the midpalatal suture, asymmetry, and the presence of bone fragments and spicules in the region, as well as differentiated moments of new bone formation during remodelling of the region. These differentiated characteristics of the opening of the midpalatal suture were also observed by Bell (1982).

In relation to suture mineralization, the radiographic findings were similar to those reported in the literature (Ekström *et al.*, 1977; Ten Cate *et al.*, 1977; Bell, 1982; Arat *et al.*, 2003), all of whom observed ossification in a perpendicular direction from the bone margins to the centre, initiating in the posterior region towards the medium region of the suture, and finally the occurrence of mineralization in the anterior and medium regions (Figures 1A–1F). The gradual increase in radiopacity in the expanded suture throughout the retention period is also in agreement with the reports of those authors.

Comparison of pixel values of the areas evaluated at the different treatment stages revealed that the mean values at T6 had not reached the T1 values. This difference in OD values was significant, at $P < 0.05$ for all other areas (Table 1). These results are in accordance with those of Sannomiya *et al.* (2007) who investigated bone density by OD analysis immediately and 3 months after SARME and observed that after this period, new bone formation at the midpalatal suture was still not complete. This finding is contrary to that of a previous study (Ekström *et al.*, 1977) conducted on young patients or experimental models, which reported complete remineralization and remodelling of the suture after 3 months of retention, possibly due to the different ages of the individuals, influencing the process of suture remodelling. This is delayed in older subjects compared with young individuals and children (Brin *et al.*, 1981; Kanekawa and Shimizu, 1998; Arat *et al.*, 2003).

In general, a period of retention is recommended, keeping the expander in place for 3 months, followed by 6 months of retention with a removable appliance or transpalatal bar (Bell, 1982; Bishara and Staley, 1987; Betts *et al.*, 1995). This protocol may be sufficient for young patients and children; however, the results of the present study demonstrated that at T6 there was not sufficient ossification to re-establish OD and the initial configuration of the midpalatal suture in the adult patients evaluated.

The factors that are important in SARME stability (Northway and Meade, 1997; Byloff and Mossaz, 2004) indicate that for adult patients treated with SARME, the retention period should be controlled and extended according to individual variations with regard to remodelling of the orthopaedically expanded suture, thereby maximizing outcome and treatment stability until the expanded suture region is completely mineralized. A radiographic control is suggested before removal. The occlusal radiograph is a convenient and cost-effective method to demonstrate suture opening, control treatment, and follow-up ossification (Betts *et al.*, 1995).

Additionally, it was observed that the results obtained with the digitized image method corresponded to those of visual analysis of conventional radiographs, allowing quantitative analysis of the data. Thus they may be used as a complementary method in clinical practice.

These radiographic results and their implications in orthodontic practice reveal the need for long-term studies to evaluate the ideal period of retention in adult patients, to allow complete remodelling of the suture, and reorganization of tissues and structures following SARME.

Conclusions

1. The pixel values on digitized radiographs presented variations between the immediate post-expansion and retention periods.
2. OD, represented by pixel values, was increased at T6; however, these values were not fully compatible with those observed at T1, demonstrating that this period was not sufficient for the re-establishment of OD and hence unable to promote complete new bone formation and bone remodelling at the suture.

References

- Anttila A, Keski-Nisula K, Somppi M, Panula K, Peltomäki T 2004 Feasibility and long-term stability of surgically assisted rapid maxillary expansion with lateral osteotomy. *European Journal of Orthodontics* 26: 391–395
- Arat Z M, Gökalp H, Atasever T, Türkkahraman H 2003 Technetium-labeled methylene diphosphonate uptake in maxillary bone during and after rapid maxillary expansion. *Angle Orthodontist* 73: 545–549
- Atac A T A, Karasu H A, Aytac D 2006 Surgically assisted rapid maxillary expansion compared with orthopedic rapid maxillary expansion. *Angle Orthodontist* 76: 353–359
- Attamelman A, Borg E, Gröndhal H G 2000 Digitisation and display of intra-oral films. *Dentomaxillofacial Radiology* 29: 97–102
- Babacan H, Sokucu O, Doruk C, Ay S 2006 Rapid maxillary expansion and surgically assisted rapid maxillary expansion effects on nasal volume. *Angle Orthodontist* 76: 66–71
- Bell R A 1982 A review of maxillary expansion in relation to rate of expansion and patient's age. *American Journal of Orthodontics* 81: 32–37
- Bell W H 1992 Modern practice in orthognathic and reconstructive surgery. W B Saunders Co., Philadelphia
- Berger J L, Pangrazio-Kulbersh V, Borgula T, Kaczynski R 1998 Stability of orthopedic and surgically assisted rapid maxillary expansion over time. *American Journal of Orthodontics and Dentofacial Orthopedics* 114: 638–645
- Betts N J, Vanarsdall R L, Barber H D, Higgins-Barber K, Fonseca R J 1995 Diagnosis and treatment of transverse maxillary deficiency. *International Journal of Adult Orthodontics and Orthognathic Surgery* 10: 75–96
- Bishara S E, Staley R N 1987 Maxillary expansion: clinical implications. *American Journal of Orthodontics and Dentofacial Orthopedics* 91: 3–14
- Brin I, Hirshfeld Z, Shanfeld J L, Davidovitch Z 1981 Rapid palatal expansion in cats: effect of age on sutural cyclic nucleotides. *American Journal of Orthodontics* 79: 162–175
- Brosh T, Vardimon A, Ergatudes C, Spiegler A, Lieberman M 1998 Rapid palatal expansion. Part 3: strains developed during active and retention phases. *American Journal of Orthodontics and Dentofacial Orthopedics* 114: 123–133
- Byloff F K, Mossaz C F 2004 Skeletal and dental changes following surgically assisted rapid maxillary expansion. *European Journal of Orthodontics* 26: 403–409
- Cobo J M, Vijande M, Suarez-Quintanilla D S 1992 Evaluation of maxillary disjunction with bone densitometry. *Journal of Clinical Orthodontics* 26: 107–110
- Dahlberg G 1940 Statistical methods for medical and biological students. Interscience, New York
- Ekström C, Henrikson C O, Jensen R 1977 Mineralization in the midpalatal suture after orthodontic expansion. *American Journal of Orthodontics* 71: 449–455
- Garrett B J *et al.* 2008 Skeletal effects to the maxilla after rapid maxillary expansion assessed with cone-beam computed tomography. *American Journal of Orthodontics and Dentofacial Orthopedics* 134: 8.e1–8.e11
- Glassman A S, Nahigian S J, Medway J M, Aronowitz H I 1984 Conservative surgical orthodontic adult rapid palatal expansion: sixteen cases. *American Journal of Orthodontics* 86: 207–213
- Haas A J 1980 Long-term posttreatment evaluation of rapid palatal expansion. *Angle Orthodontist* 50: 189–217
- Holberg C, Steinhäuser S, Rudzki-Janson I 2007 Rapid maxillary expansion in adults: cranial stress reduction depending on the extent of surgery. *European Journal of Orthodontics* 29: 31–36
- Houston W J B 1983 Analysis of errors in orthodontics measurements. *American Journal of Orthodontics* 83: 382–390
- Kahl-Nieke B 1996 Retention and stability considerations for adult patients. *Dental Clinics of North America* 40: 961–992
- Kanekawa M, Shimizu N 1998 Age-related changes on bone regeneration in midpalatal suture during maxillary expansion in the rat. *American Journal of Orthodontics and Dentofacial Orthopedics* 114: 646–653
- Lione R, Ballanti F, Franchi L, Baccetti T, Cozza P 2008 Treatment and posttreatment skeletal effects of rapid maxillary expansion studied with low-dose computed tomography in growing subjects. *American Journal of Orthodontics and Dentofacial Orthopedics* 134: 389–392
- Melsen B 1975 Palatal growth studied on human autopsy material. A histologic microradiographic study. *American Journal of Orthodontics* 68: 42–54
- Northway W M, Meade Jr J B 1997 Surgically assisted rapid maxillary expansion: a comparison of technique, response, and stability. *Angle Orthodontist* 67: 309–320
- Pogrel M A, Kaban L B, Vargervik K, Baumrind S 1992 Surgically assisted rapid maxillary expansion in adults. *International Journal of Adult Orthodontics and Orthognathic Surgery* 7: 37–41
- Proffit W R, Turvey T A, Phillips C 1996 Orthognathic surgery: a hierarchy of stability. *International Journal of Adult Orthodontics and Orthognathic Surgery* 11: 191–294
- Sannomiya E K, Macedo M M C, Siqueira D F, Goldenberg F C, Bommarito S 2007 Evaluation of optical density of the midpalatal suture 3 months after surgically assisted rapid maxillary expansion. *Dentomaxillofacial Radiology* 36: 97–101
- Suri L, Taneja P 2008 Surgically assisted rapid maxillary expansion: a literature review. *American Journal of Orthodontics and Dentofacial Orthopedics* 133: 290–302
- Ten Cate A R, Freeman E, Dickinson J B 1977 Sutural development: structure and its response to rapid expansion. *American Journal of Orthodontics* 71: 622–636
- Van Der Stelt P F 2000 Principles of digital imaging. *Dental Clinics of North America* 44: 237–248